

Ohhhh My Aching Foot!!!

March 2010

Assessment and Tx of Plantar Fasciitis

The coming of spring means rebirth and rejuvenation. This also means it's time for many of us to come out of our long winter hibernation. Spring is that time of year when exercise starts to take front and center stage, because most of our clients, at this point, are concerned about their lack of exercise through the winter and their bulging waist line. With that come some common mistakes by our overzealous clients. A few universal traits to look for with your clients:

Are they pushing themselves too hard?

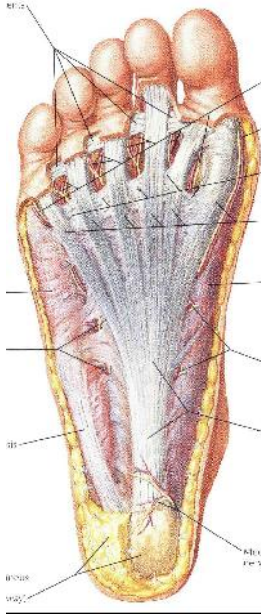
Are they stretching?

Are they balancing their exercise so not to over-strengthen one particular area while ignoring others?

If they fall under any of these criteria, then they may be setting themselves up for an injury that will hamper their desire for exercise / weight loss. As bodyworkers, in many instances we step in before the injury occurs, and there is no ballyhoo for the preventive side of bodywork. Does the client know we saved them from a possible debilitating hamstring injury in June, or that nasty piriformis syndrome in September? Nope, that side of the work goes unnoticed until the client stops using our services and limps back into the office six months later saying, "fix me, I'm broken". And we just shake our heads and say "No Duhh, you should have, at minimum, been here for maintenance on a semiannual basis". Well, we really don't say "No Duhh" to our clients, but my inside voice sure is screaming it. Whew, thank goodness for my filter that prevents those lil' things from bursting forth out of my lips.

One of the common injuries associated with new activities is **plantar fasciitis**.

Let's review the **anatomy of the plantar fascia** (PF). The plantar fascia is located on the bottom of the foot deep to the skin and adipose layer of the plantar surface of the foot. The PF attaches onto the anterior calcaneus on one end and the five metatarsal heads and phalanges on the distal end.



In the picture to the above, the plantar fascia is the superficial layer and is AKA the plantar aponeurosis.

One of the functions of the PF is to help maintain the integrity of all the arches, but its main focus of arch support is on the integrity of the medial longitudinal arch. The MLA is the long arch associated with the inside of the foot.

Another extremely important function of the PF is with walking, when the push-off phase of walking is taking place, the PF is pulled taught acting like a spring, the toes go into extension during push-off. This helps to create kinetic energy to propel the body forward. (Kinetic energy is energy of motion. The kinetic energy of an object is the energy it possesses because of its motion.) Think of a rubber band running from the heel to the toes, and the rubberband is being stretched every time you move the toes to the nose (extension). Well, the rubberband is creating energy to pull the toes back down into neutral position, and with push-off during walking the plantar fascia is helping to thrust you forward... energy in motion = kinetic energy.

Now that we have an understanding of where and what the plantar fascia is, lets take a look at; **"What is plantar fasciitis"?**

Plantar fasciitis is an inflammatory condition involving the plantar fascia near the calcaneal attachment. There is controversy about the "inflammatory" part of plantar fasciitis. It is now being looked at in the same context as tendonitis and tendinosis conditions. The inflammatory response is a reaction to injury or a repetitive stress injury (RSI). The "itis" part of this condition may last up to a month and is typically near the calcaneal attachment, which is much smaller and a more focused attachment then the distal attachment of the five tendons that run up to the toes. The tensile forces coming from all five toes tend to pull heavily on one central point, the calcaneus. Lets also remember our anatomy, the tendons do not actually attach to the osseous tissue. Right? The tendons attach to the periosteum which is

loaded with pain receptors, so this injury tends to be extremely painful. The pulling on the periosteum also creates stress loads on the bone which is a signal for bone growth. If this new growth occurs, it maybe in the form of a bone spur because of the localized pulling of the plantar fascias attachment on the calcaneus.

Plantar fasciitis can often be the result of pronation of the foot, AKA flat foot (eversion). Pronation results in the plantar fascia becoming over-stretched and creating a constant tension in the fascia. This pronation is a biomechanical dysfunction which results in the medial arch lowering to the ground. One of the functions of the arch is to act as a shock absorber, so when the arch lowers to the ground it loses some of its shock absorber qualities. Which in turn, the plantar fascia will then get recruited to increase its overall role in shock absorption. While the plantar fascia is being stretched out due to the pronation, then being asked to act as a shock absorber, the plantar fascia is placed into a scenario for a biomechanical stress injury. Imagine taking a rubber band and stretching it to its max, then ask the rubber band to function for a little extra elasticity.... Snap! Or in the case of the plantar fascia pull... tug... pull... tug... on the periosteum of the calcaneal attachment.

Now that I have convinced you that a pronated arch is the major contributor, I have to add a little confusion to the scenario. A supinated arch can also be a contributor to plantar fasciitis. A supinated arch is an arch moving in the opposite direction... not down towards the floor but up towards the ceiling (inversion). It is a high arch and may be high due to a short plantar fascia which pulls the heads of the metatarsals closer to the calcaneus. Think about having a piece of paper lying flat on a table top and you take the two ends of the paper (i.e. heads of the metatarsals on one end and the calcaneus on the opposite end) and gently push the two ends towards one another. What happens? The center of the paper bows up as in a supinated arch.

Assessment

When assessing a client with plantar fasciitis a thorough subjective assessment should be utilized. *1. Is your client starting new high impact exercises?* For instance, are they running or playing basketball on hard surfaces. *2. Is your client waking-up with plantar foot pain?* While sleeping the foot is in plantar flexion, so that leads to the plantar fascia being put into a shortened position for a prolonged period of

time. Upon rising from bed, the client often experiences pain due to the tissue being shortened and needing to re-stretch. *3. Is the pain located anterior to the calcaneus?* Remember the discussions above, anterior to the calcaneus is where the greatest tensile stress is being placed. As far as a bone spur, which was discussed earlier, an X-Ray will be the best and easiest assessment for the spur.

Treatment

Treating the plantar fascia consists of treating the site of pain, as well as, treating the surrounding tissue that is myofascially continuous with the plantar fascia. When treating the plantar fascia be aware that the site of discomfort, anterior to the calcaneus, may be extremely tender & contain a bone spur. While treating, closely monitor client's discomfort to properly ensure comfortable treatment level. Since the plantar fascia is short, elongation techniques to the plantar fascia by utilizing a loose fist or longitudinal thumb stripping will begin to create length in the plantar fascia. Cross fiber techniques to the plantar fascia will help to stimulate fibroblasts which will help the repair process of the fascia.

Treatment of the tissue that is fascially continuous with the plantar fascia is also beneficial to the healing process. To look at the myofascial chain, from the plantar fascia connection on the calcaneus, the chain would continue over the calcaneus proximally to the Achilles tendon. Treatment of the muscles that connect to the Achilles tendon is also needed due to the pulling forces on the calcaneus. Elongation of the two heads of gastrocnemius and soleus will help to ensure a quick and thorough healing. Cross fiber friction may also be employed to any adhesions found in the bellies of the aforementioned muscles.

Treatment of all the muscles of the lower leg may be beneficial because of the biomechanical compensation patterns. Due to biomechanical dysfunctional patterns in the foot, a trained orthodist may be beneficial for proper fitting of orthotics, which will help the stress patterns of the plantar fascia. Clients should be given stretches to the gastrocnemius and soleus and perform the stretches upon rising from bed and continue stretches throughout the day. Other suggestions for the client are using a tennis ball on the plantar surface and icing the bottom of the foot with a bag of peas that will contour to the shape of the foot.

I hope this helps with your next plantar fasciitis client.

Jeff Mahadeen, LMT, NCBTMB, Certified Structural Integrator